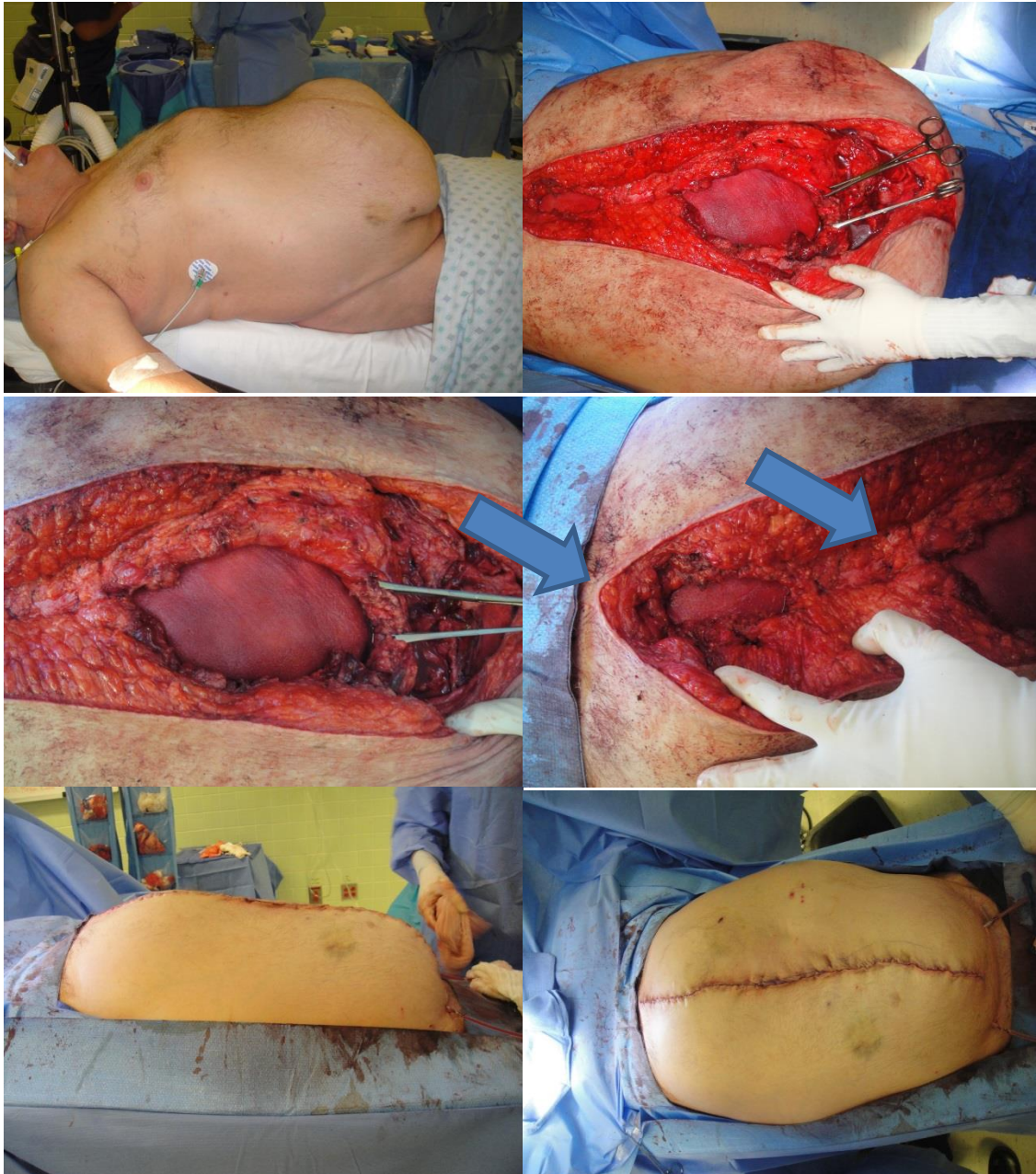


## Custom Repriza® for Two Abdominal Hernias in Same Patient



**A) Top Left: Patient with pneumoperitoneum on OR table. One massive lower abdominal wall hernia and one large epigastric hernia.**

**B) Top Right: Repriza ADM underlay at both hernias, epigastric and lower abdominal wall sites.**

**C) Middle Left: Large underlay at site of larger lower abdominal wall hernia before closure.**

**D) Middle Right: Smaller underlay at site of epigastric hernia. Arrows point to both defects.**

**E) Lower Left: Abdomen closed, lateral view.**

**F) Lower Right: Abdomen closed, anterior view.**